Symptoms related to the cervical region

- Riding problems – stiffness in the neck
- Forelimb lameness
- Hind limb weakness
- Ataxia/wobbler

Symptoms related to the cervical region

- Anatomy
- Symptoms
- Diagnostics
- Treatment

Anatomy

- Cervical vertebrae
- Joints, facet joints
- Nerves, CNS – spinal cord, periferal nerves
- Muscles
- Skin, bloodvessels, trachea, oesaphagus, etc.

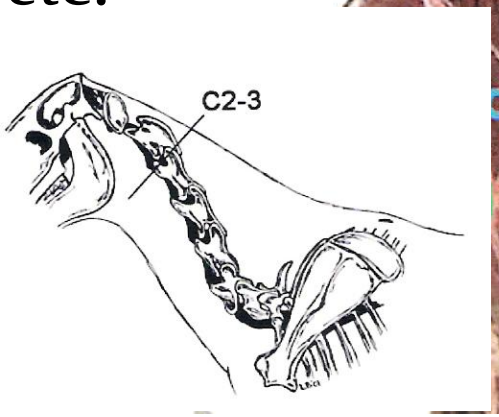

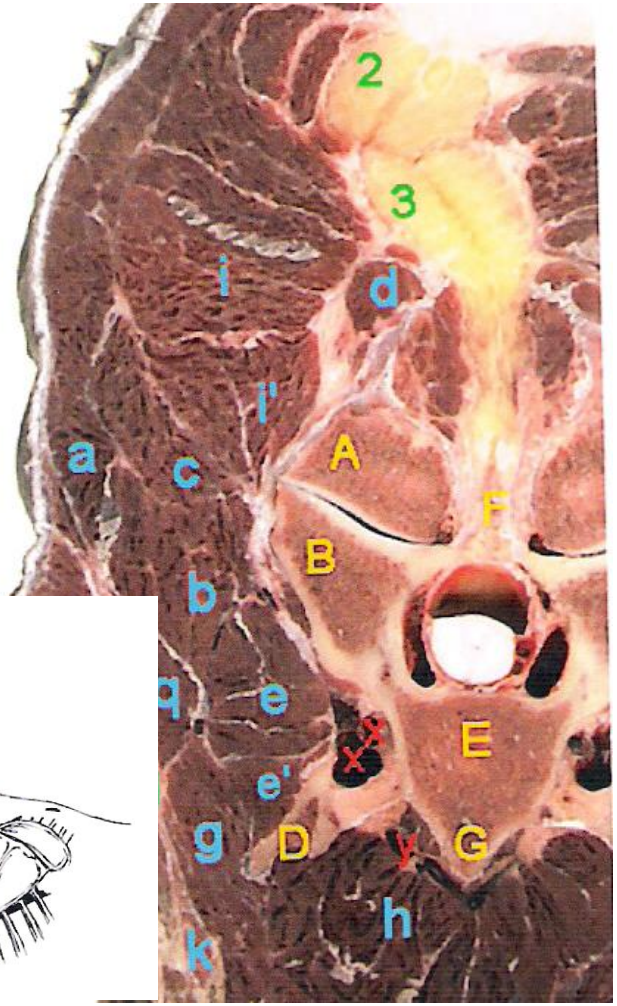

Spinal cord

3 types of nerves

- Pain
- Muscle contraction
- Proprioception – the signal from tendons and muscles

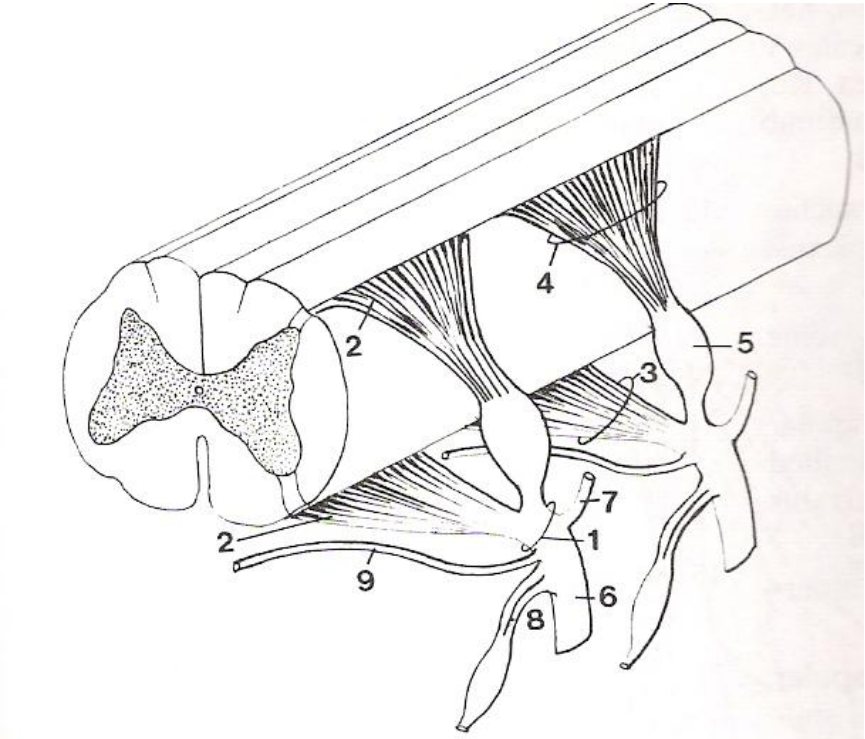

A Nervi spinales, roots and branches

Spinal cord

Simplified nerve placement

- Proprioception – signals from the muscles and tendons
- Muscle contraction
- Pain

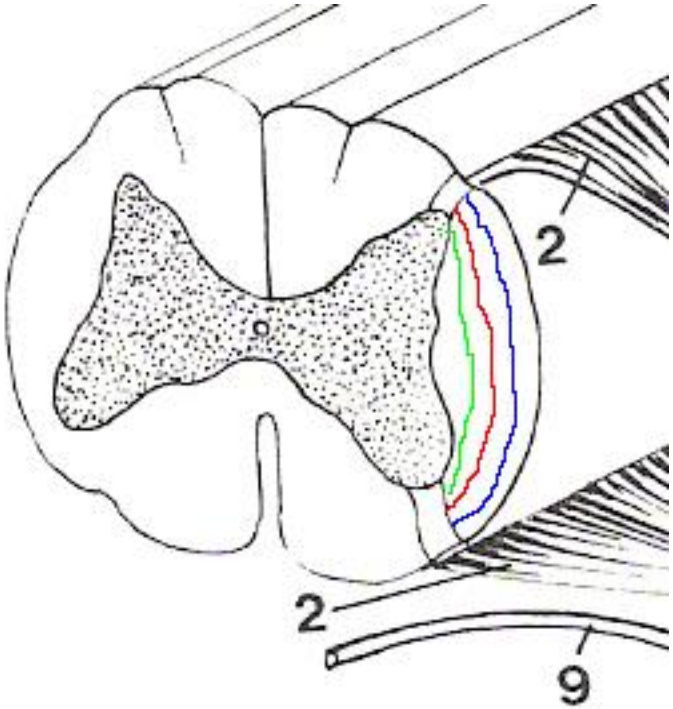

Spinal cord

Cervical spinal cord:

Nerves to the hind limbs most abaxial

Nerves to the front limbs most axial

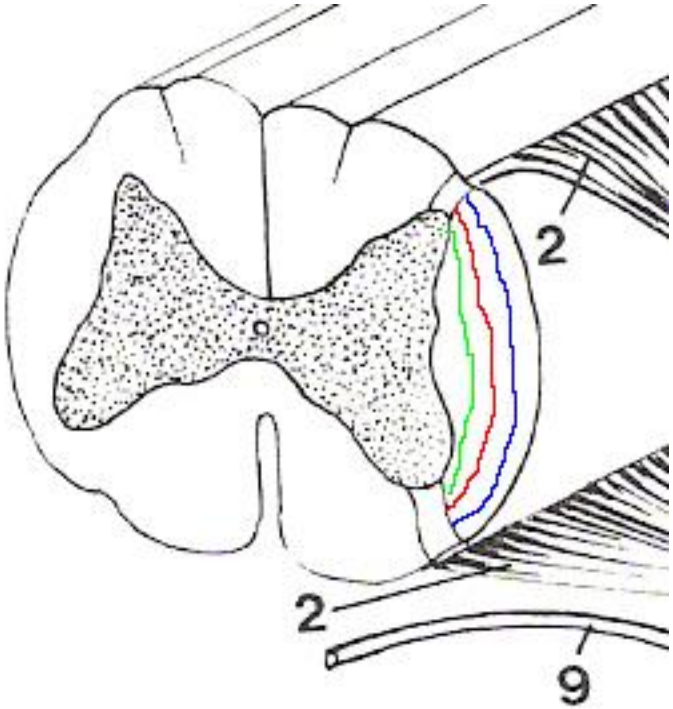

Remember the brachiocephalic plexus

C5-T2

The relation to symptoms

Spinal cord compression:
Affecting hind limbs first
- then the front limbs

- Lack/reduced coordination
- Paralysis
- Reduced pain perception

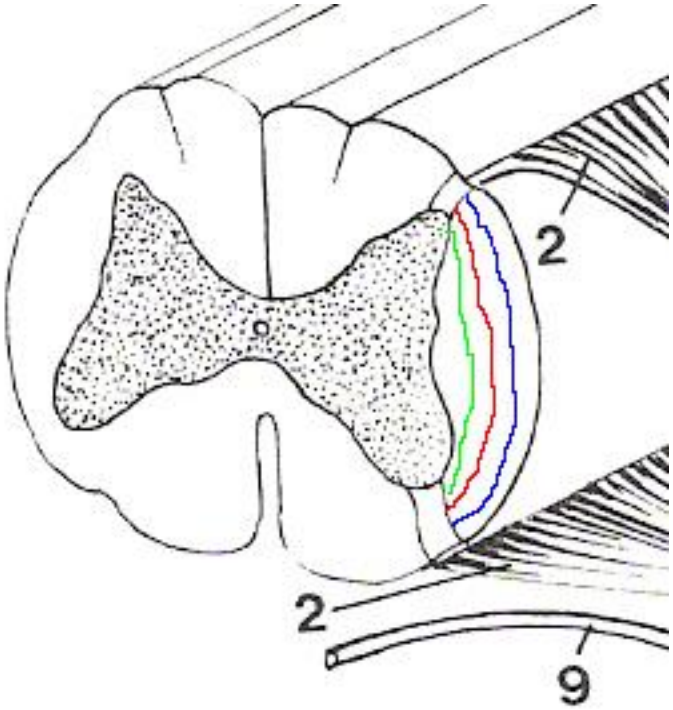

Spinal cord compression

- Facet joint
  - Osteoarthrosis/new bone formation
  - OCD
  - Facet joint effusion
  - Fractures
- Cervcal vertebraes
  - Congenital malformations
  - Instability
  - Fractures

The relation to symptoms

Spinal cord compression:
First the hind legs
- then the front legs

- Reduced coordination
- Paralysis
- Reduced pain perception

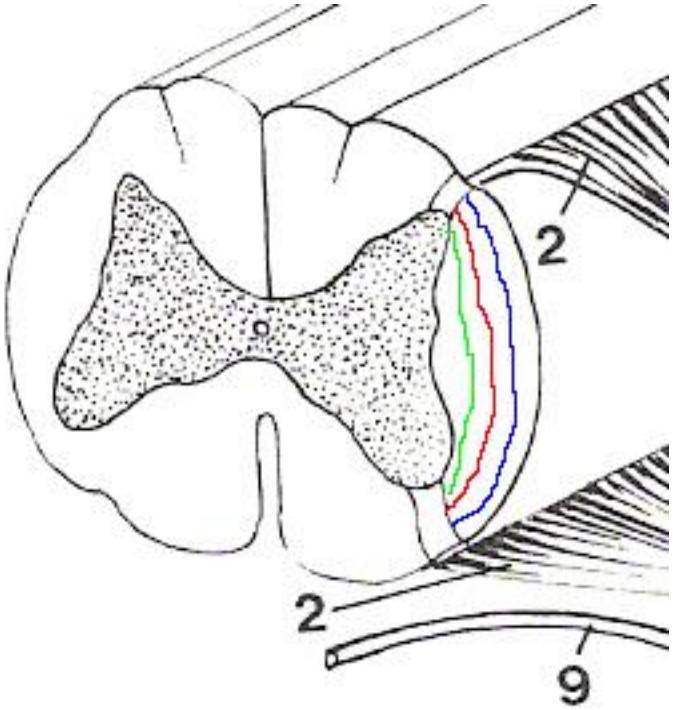

Compression of nerves/spinal cord

- Compression at the brachiocephalic plexus

  Obscure forelimb lameness which can not be reduced by diagnostic analgesia

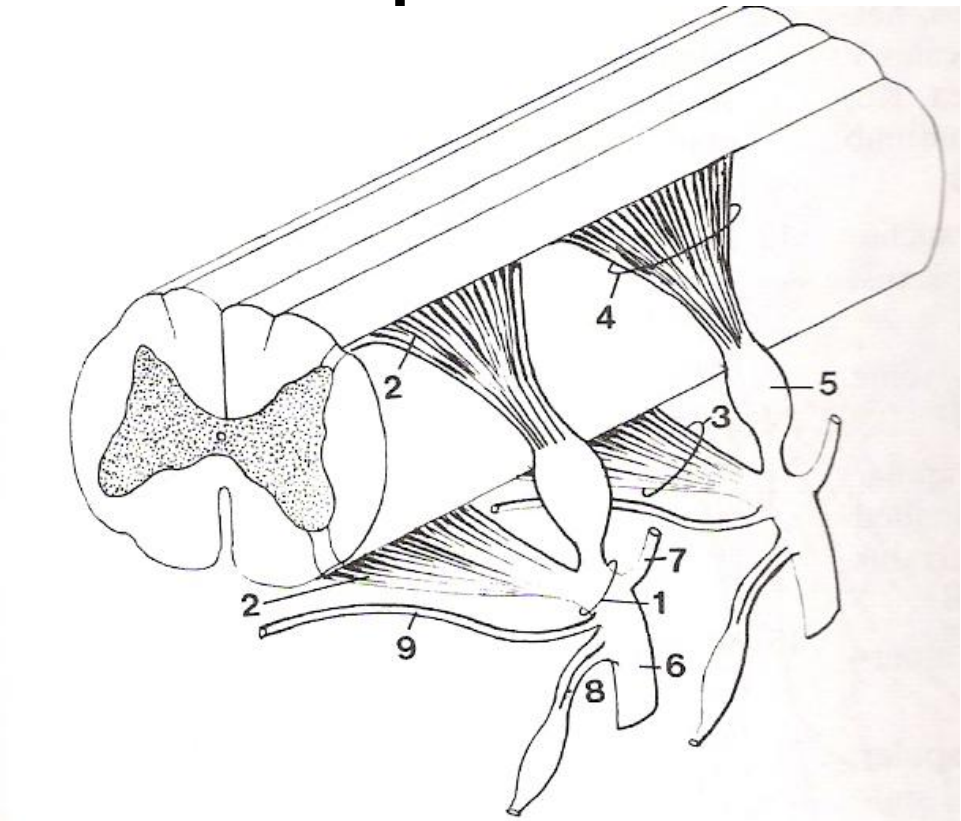

A Nervi spinales, roots and branches

Ataxia/Wobbler

Hindlimb weakness

Vestibular cochlear syndrome

Diagnostics

- Clinical – symptoms
  - Trot up
  - Lounge
  - Coordination tests
    - Tail pull
    - Tight circle
    - Walk backwards
    - Ramp

Diagnosis

- Clinical examination
- X-ray
- Scanning
- Myelography - contrast

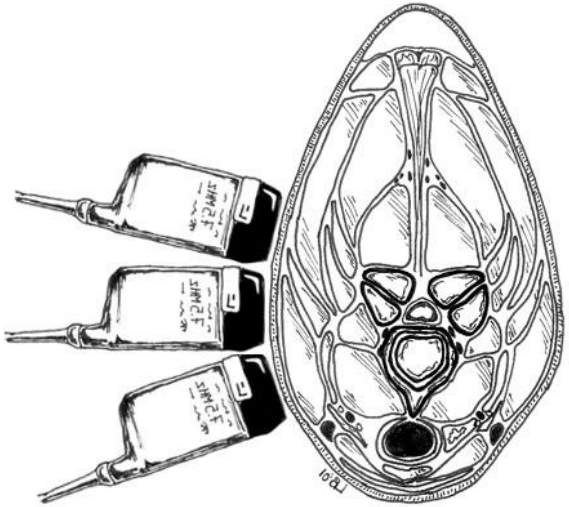

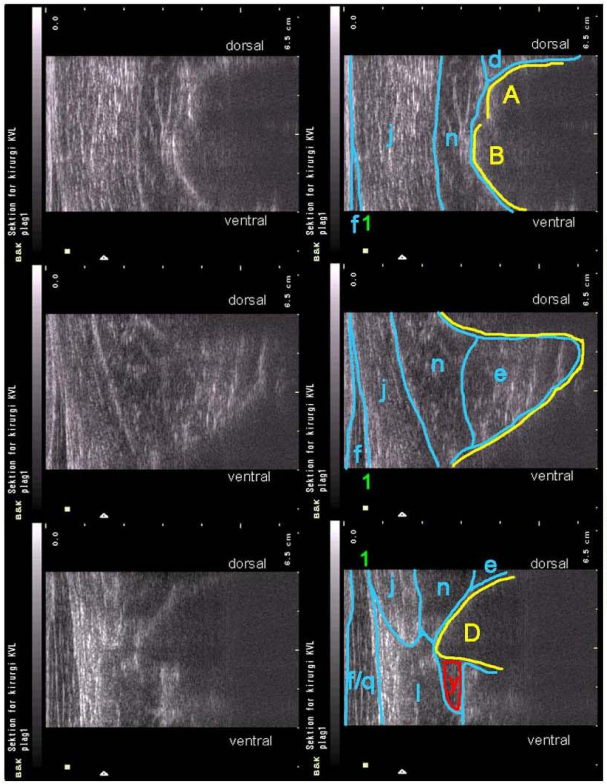

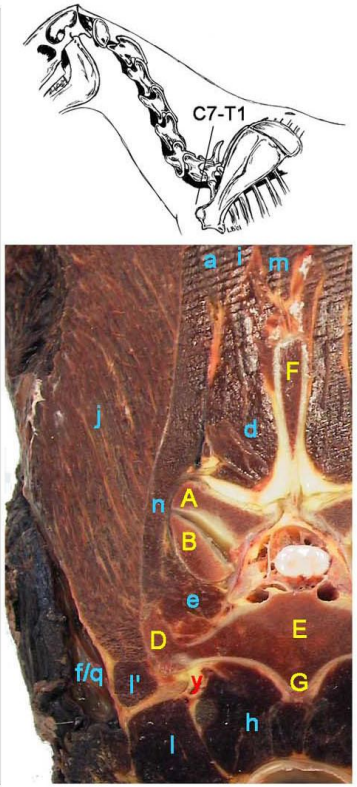

Fig 13: Identifiable structures on ultrasound images and anatomical cross section at the level of C7-T1. Muscles: M. splenius (a), *mm. multifidii cervicii* (d), *mm. intertransversarii cervicii* (e), *m. brachiocephalicus* (f), *m. longus colli* (h), *m. semispinalis capitis* (i), *m. serratus ventralis cervicis* (j), *m. scalenus ventralis* (l), *m. scalenus medius* (l'), *m. spinalis cervicis* (m), *m. longissimus cervicis* (n), *m. omotransversarius* (q). *Vertebral: Processus articularis caudalis* (A), *processus articularis cranialis* (B), *processus transversus* (D), *corpus vertebra* (E), *processus spinosus* (F), *crista ventralis* (G). *Misc.: Fascia cervicalis* (1), *rami from vertebral vessels* (y)

Treatment

- Intra-articular facet joint injection
  - Joint medication
- Time and box rest - trauma/joint effusion
- Euthanasia
  - Safety rider/owner
  - Animal welfare